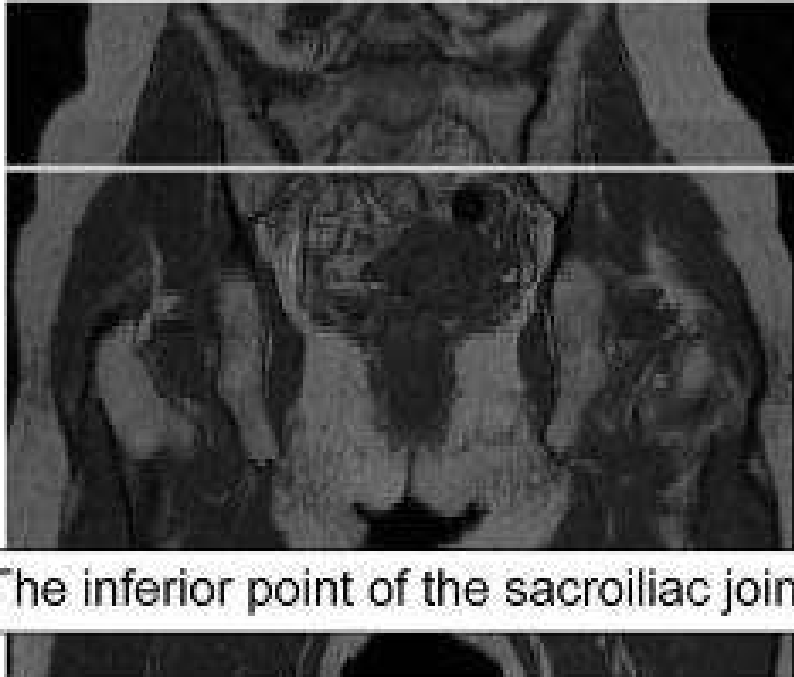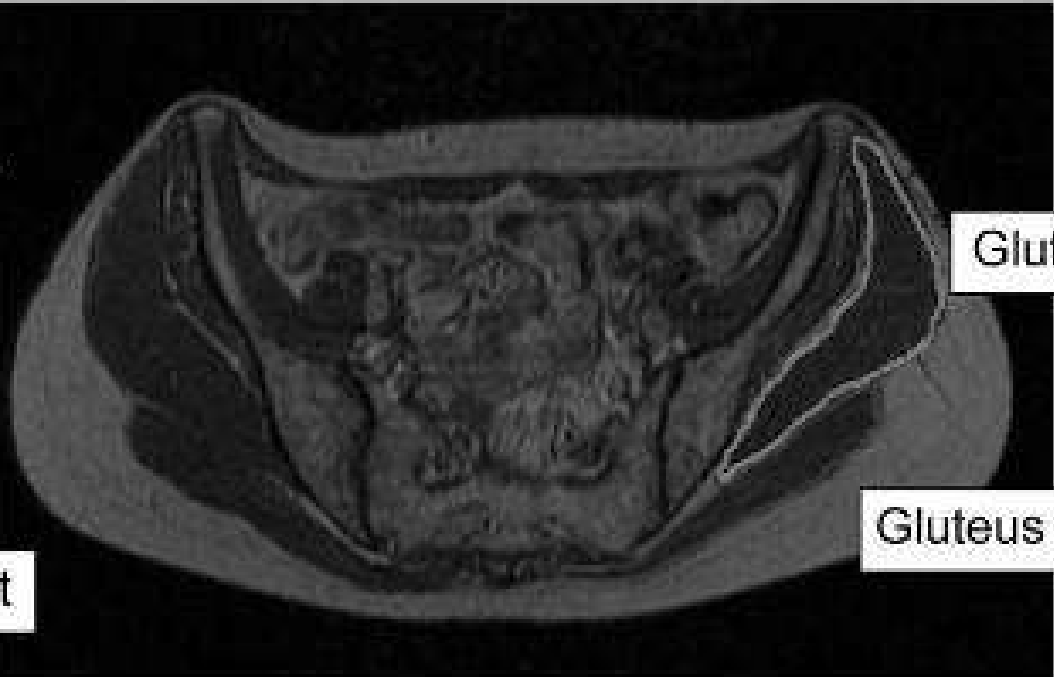




The inferior point of the sacroiliac joint



Gluteus medius

Gluteus maximus